

34 Congenital Pseudarthrosis of the Tibia

Mahmoud A. EJ-Rosasy

Department of Orthopedic Surgery, Tanta University, Tanta, Egypt

Dror Paley and John E. Herzenberg

Rubin Institute for Advanced Orthopedics, The International Center for Limb Lengthening, Sinai Hospital, Baltimore, Maryland, U.S.A.

INTRODUCTION

Congenital pseudarthrosis of the tibia (CPT) refers to nonunion of a tibial fracture that develops spontaneously or after trivial trauma in a dysplastic bone segment of the tibial diaphysis. The pseudarthrosis usually develops during the first two years of life; however, there are reports of cases in which fractures developed before birth and reports of late-onset pseudarthrosis. The etiological nature of this condition is unclear; however, there is a strong association between CPT and neurofibromatosis Type I (NF-I). CPT develops in about 5.7% of patients with NF-I. On the other hand, 40% of patients with CPT were found to have NF-I. Electron microscopy and histopathological studies showed that the main pathology of CPT is hyperplasia of fibroblasts with the formation of dense fibrous tissue. This invasive fibromatosis is located in the periosteum and between broken bone ends and surrounds the tibia causing compression, osteolysis, and persistence of pseudarthrosis (1-3).

Classification of CPT has been attempted based on time of onset, mobility, and radiological appearance. It is well known that CPT may be preceded by cystic and hourglass constriction of the bone or by fatigue-like fracture of the tibia. Difficulties have arisen because the condition includes several different clinical and pathological entities, each having a different history and prognosis. The use of a classification system that is based on the radiological appearance of the tibia can become confusing in that the pattern can change from one variety to another during treatment. Thus, what may first appear as a cystic lesion with an apparently good prognosis may, after one or two attempts at grafting, appear as a dysplastic lesion with a less-favorable prognosis (4,5).

To date, there is still no clear, universally accepted classification system based on both radiological and clinical appearance. This indicates that none of the proposed classification systems are based on a totally accurate concept of the cause, natural history and treatment result.

CPT remains one of the most perplexing and challenging orthopedic problems. This is because of difficulty of obtaining union and, in cases that achieve union, difficulty of maintaining union. Frequently, the end result of this scenario is a frustrated child who has undergone several failed operations and has a limb that is short, deformed, and almost functionless. This experience led some authors to advise amputation if the third operation failed to achieve bone union and a functioning limb (5,6).

The difficulty in treating this condition occurs because of two factors. The first is biologic: poor healing ability of the dysplastic segment of bone. The second factor is mechanical: technical difficulty to fix small and osteopenic bone fragments in children without damaging the distal tibial physis or ankle joint.

A multitude of treatment protocols have been described and have varying degrees of success (7). Most of these treatments focused on stimulating the healing process by using different bone grafting techniques. The graft materials most commonly used included osteoperiosteal graft, massive onlay graft, autogenous iliac crest bone graft (ICBG), and vascularized bone graft (1,8-10). The fixation methods also varied widely between cortical fixation using bone or metal plates, intramedullary (IM) rods of different types, external skeletal fixation, and lastly external skeletal fixation augmented by IM rod (1,11-15).

Whatever the treatment method used, the natural history of CPT is that the affected bone segment remains atrophic and poorly consolidated with a tendency to refracture until skeletal maturity. At skeletal maturity, the bone quality, for unclear reasons, becomes almost normal, hypertrophy of the tibia occurs, and then the bone ceases to refracture (1,5).

CPT continues to pose a difficult therapeutic challenge in both achievement of bone healing and maintenance of this healing.

Paley (15) theorized that the pathology of congenital pseudarthrosis is not bony but rather periosteal in origin. Anatomically and physiologically, this theory is supported by the following observations: thickening with hamartomatous transformation of the periosteum, appearance of strangulation of the bone with atrophic changes followed by avascular changes (the anterolateral bowing of the bone is due to the dominant muscular forces on the leg from the eccentrically located posterolateral muscle masses), and failure of remodeling of pin holes leading to stress fracture (remodeling is a periosteal function). This theory was considered by Codavilla a century ago. In 1975, Cambras from Cuba used the periosteum and bone from the mother to treat CPT. Cambras considered the periosteum to be the source of the pathology (personal communication). Most recently, pathologic analysis by Hermans-Sachweb et al. confirmed that pathologic periosteum is the cause of CPT (16). Their most striking finding was that neural cells formed a tight sheath around the periosteal arteries reminiscent of the way Schwann cells in the periosteum cause narrowing or obliteration of the periosteal vessels. The periosteum undergoes hypoxic degeneration resulting in the formation of a thick fibrous cuff. This leads to impaired oxygen and nutrient supply to the subperiosteal bone and the atrophic bone changes that are observed. As will be described below, Paley has used periosteal grafts successfully in the treatment of CPT. Paley's method has been independently corroborated by Grill from Austria and Kocaoğlu from Turkey.

CLINICAL EVALUATION

The management of a case of CPT starts with general clinical evaluation for presence of NF-I and its consequences that might affect the quality of the patient's life and may temper the enthusiasm to achieve bone healing. In some cases, the treating surgeon would resort to other treatment methods such as amputation and prosthetic replacement (2,5).

The patient's history of the onset of fracture and previous surgical treatment has important prognostic and therapeutic implications.

The affected limb of the patient is examined for mobility or stiffness of the pseudarthrosis, presence of deformity, nearby joint stiffness, previous operative scars, quality of soft tissues, and neurovascular abnormalities.

Radiological examination of the affected leg in the anteroposterior and lateral views is used to determine the level of CPT, quality of bone, presence of retained hardware, and condition of nearby joints. Full-length standing radiographs of both lower limbs are obtained to determine leg-length discrepancy, mechanical axis deviation, and presence of deformities (17).

CLASSIFICATION

A comprehensive classification system should serve therapeutic guidelines, provide prognostic indicators for the condition under study, and consider all the factors that influence treatment options. Meanwhile, the classification should be easy to recall and apply. Recognizing these facts, we developed our classification based on the clinical observations and results of the treatment of 17 patients with CPT and our review of literature.

Our classification (Table 1) considers the patient's condition at the time of treatment and is based on three parameters: (i) Did the patient have any surgical treatment for the pseudarthrosis or not? Previously failed surgical treatment negatively affects the prognosis due to less favorable soft tissue condition and bone quality and possibly retained hardware. (ii) Is the pseudarthrosis of the mobile or stiff type? Mobile pseudarthrosis means presence of intervening abundant fibrous tissue, which requires operative excision and implies a poorer prognosis than the stiff type. (iii) Plain X-ray examination of the affected leg for the radiological typing of CPT: atrophic with narrow bone ends or hypertrophic with wide bone ends. Based on these findings, three types of CPT were recognized (Fig. 1).

Table 1 El-Rosasy-Paley Classification for CPT

Type I	Atrophic bone ends (based on radiographic examination) Mobile pseudarthrosis
Type II	No previous surgical intervention Atrophic bone ends (based on radiographic examination) Mobile pseudarthrosis
Type III	Previous surgical intervention with or without retained hardware Broad bone ends (based on radiographic examination) Stiff pseudarthrosis With or without previous surgical intervention

Two years of age/ and have a good prognosis. Type II pseudarthrosis presents usually in older children after experiencing failed surgical treatment/ refracture/ or an osteotomy to correct a bow-leg. Type III cases have a relatively poorer prognosis. Type III cases are usually of late onset. The best prognosis.

TREATMENT OPTIONS

Whatever the method used to treat CPT certain requirements should be fulfilled to ensure good results: (i) Complete excision of the soft tissue fibromatosis at the site of pseudarthrosis with minimal bone resection, (ii) Stimulation of bone healing by insertion of autogenous ICBG. (iii) Proper fixation of the bone fragments into bone healed is observed radiologically. (iv) Maintenance of complete bone consolidation and hypertrophy at the age of skeletal maturity (1,9,12-14,18) (Table 2).

Our preferred method of fixation is to use Ilizarov external fixator augmented by IM rod. The Ilizarov external fixator facilitates fixation of small bone fragments and simultaneous compression of pseudarthrosis, gradual correction of deformities, leg lengthening, and bone transport. The use of an IM rod augments the fixation of osteoporotic bone and prevents axial deviation of bone fragments during compression-distraction. The IM rod remains in the bone indefinitely after fixator removal to act as internal splint and to protect the tibia against refractures.

Table 2 Review of Literature

Reference	Number	Title	Number of Patients	Results	Conclusions
(15)		Treatment of CPT using the Ilizarov Technique	15 (16 cases)	94% united, 31% ReFx, No IM rod	Correct angular deformities, maximize cross section of bone
(11)		CPT associated with neurofibromatosis-1 treatment with Ilizarov device	21	66.7% united, 23.5% ReFx, 33.3% nonunion, 2 IM rods	CPT resection, + Ilizarov device, + postoperative compression
(3)		CPT: Part I: European pediatric orthopedic society, multicenter study of congenital pseudarthrosis	340	Ilizarov Tx, + ICBG, 75% healing; vascularized fibUla, 61% healing	Ilizarov Tx and ICBG or vascularized fibula, + prophylactic 1M rod
(14)		CPT: results of technical variations in the Charnley-Williams procedure	23	87% good, 13% unsatisfactory	Pseudarthrosis, excision + autogenous graft, + fibular surgery, + dual 1M rod
(12)		Use of an 1M rod for the treatment of CPT. A long-term follow-up study	21	76% good, 57% ReFx, 23.8% amputations	Pseudarthrosis, excision + autogenous graft, + 1M rod

Abbreviations: CPT, congenital pseudarthrosis of the tibia; ReFx, refracture; 1M, intramedullary; ICBG, iliac crest bone graft; Tx, treatment

Table 3 Clinical Management

Classification Suhgruup ¹²	Clinical Evaluation	Surgical Approach	Pearls	Complications/Pitfalls
Type I	Signs of NF-1, fibular integrity	Fibromatosis resection, ICBG, dual 1M rod, Ilizarov device	Maximize bone contact, Dual rodding	Tenuous union
Type II	Soft tissue condition, bone loss, retained hardware	Acute bone contact, ICBG, 1M rod, Ilizarov, ± Limb lengthening	Adequate graft, postoperative compression	Refracture
Type III	Deformity analysis, fibular integrity	Preconstructed frame, distraction- compression	No residual deformity, delayed 1M rod	Peroneal nerve palsy

¹²Pseudarthrosis classification followed the system described by El-Rosasy et al. (13). Abbreviations: NF-1, neurofibromatosis-1; ICBG, iliac crest bone graft; 1M rod, intramedullary rod.

SURGICAL TECHNIQUES

Based on the classification of CPT, treatment strategies are described for each type of pseudarthrosis (Table 3).

Treatment of Type I CPT

Surgery is performed soon after the tibia fractures to avoid complications that result from delayed treatment (e.g., deformity, joint contracture, and limb shortening) (Figs. 2 and 3). The pseudarthrosis is approached through a standard anterior approach to the tibia. The fibrous tissue hamartoma is carefully dissected from surrounding muscles and excised subperiosteally from the bone ends back to the limits of apparently healthy periosteum. Minimal trimming of the tapered bone ends is done to allow identification of the medullary cavity (aggressive bone resection should be avoided to minimize bone loss). The proximal bone end is drilled in the coronal plane using a thin Kirschner wire (KW.) starting from distal to proximal for a distance of 2 to 3 cm. Using a thin osteotome, the tip of the proximal end is carefully split along the drill holes. A small drill bit is used to open the medullary canal of the distal fragment. The thickest possible KW. is then inserted into the medullary canal of the distal fragment. If the ankle joint is to be transfixed, the foot should be held by an assistant in the neutral position and its position is monitored by image intensifier control. One of the authors (Dror Paley) has modified this method so that the wire is inserted disto-proximally from the medial malleolus to spare the ankle joint. The tip of the distal fragment is carefully wedged into the split end of the proximal one. This bone invagination increases bone contact, triples the cross sectional diameter of the tibia, stabilizes the pseudarthrosis, and realigns the tibia. The KW. is advanced through the medullary canal of the proximal segment until just

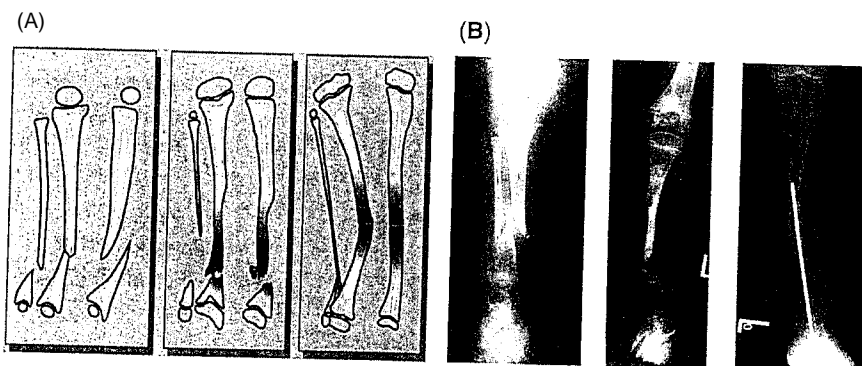


Figure 1 (A) Schematic representation and (B) radiographic examples of the El-Rosasy-Paley classification of congenital pseudarthrosis of the tibia. Type I: atrophic, mobile pseudarthrosis, and virgin type. Type II: atrophic, mobile pseudarthrosis, and previous surgical treatment. Type III: wide bone ends, stiff pseudarthroses, and ± previous surgical treatment.

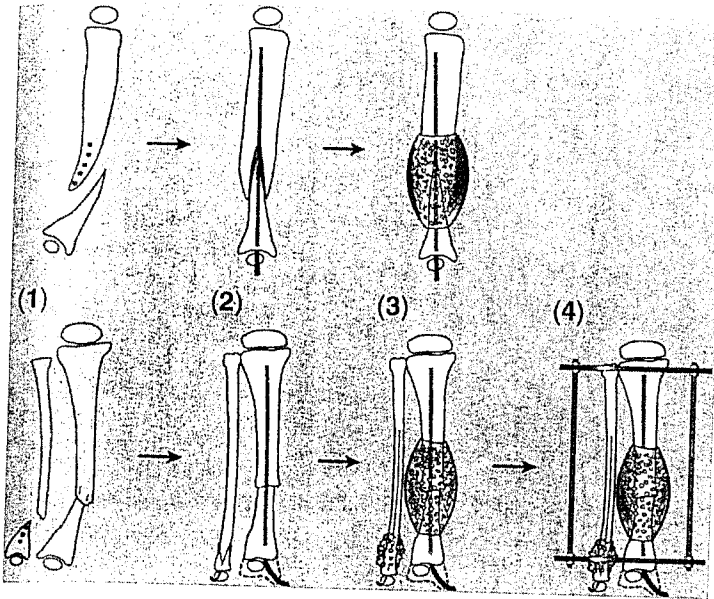


Figure 2 Type I treatment-steps in treatment. (1) Longitudinal splitting of the proximal tibial and distal fibular fragments. (2) Invagination of bone ends and insertion of intramedullary rods into the fibula and tibia through the medial malleolus to allow free ankle motion. (3) Insertion of iliac crest bone graft around the pseudarthrosis. (4) Application of the Ilizarov external fixator.

before reaching the proximal tibial physis. The KW. should span the whole tibia and should be followed under irrigation intensifier to avoid penetration into the knee joint or false passage outside the bone medullary cavity. Autogenous ICBG is harvested and packed all around the pseudarthrosis. Periosteum harvested from the undersurface of the iliacus muscle at the same time and from the same site as the cancellous bone harvest and is wrapped around the pseudarthrosis site. This periosteal graft is meshed using a skin graft mesher to allow it to expand. The periosteal graft should be placed with its cambium layer toward the bone. The wound is closed in layers.

The fibular pseudarthrosis is dealt with in a way similar to the tibia. The fibrous tissue at the pseudarthrosis is excised. A suitably sized KW. is inserted retrograde into the distal segment. The narrow tip of the proximal bone is wedged into the distal fragment which is short and broad. The KW. is advanced into the medullary canal of the fibula till reaching the upper physis. Autogenous ICBG is packed around the fibular pseudarthrosis, and the wound is closed in layers.

A two-ring pediatric Ilizarov external fixator is applied with a foot piece attached to control the foot position. No lengthening osteotomy is done for these patients due to minimal shortening (1-2 cm), which will be compensated for during growth. The pseudarthrosis is compressed for a few millimeter during the following postoperative days. The fixator remains on until complete healing is noted radiographically (average duration, four to five months). The IMrod is left as internal splint; however, it should be followed up regularly so that when




Figure 3 (A-C) Type I pseudarthrosis treatment. (A) Anteroposterior and lateral view radiographs of Type I congenital pseudarthrosis of the tibia in a six-month-old child. (B) Immediate postoperative radiographs showing dual rodding of tibia and fibula, bone grafting, and Ilizarov frame application. (C) Follow-up radiographs, two years postoperative showing consolidation of the pseudarthrosis and distal migration of the rod due to tibial growth.




Figure 4 Type II treatment. (Top row) Resection of dead bone ends, proximal lengthening osteotomy, bone transport for large bone defect, insertion of intramedullary (IM) rod and iliac crest bone graft (ICBG) at the completion of bone transport; (bottom row) resection of dead bone ends, proximal lengthening osteotomy, acute shortening for small bone defect, and insertion of IM rod and ICBG.

it is outgrown by the tibia, it can be replaced by a longer rod to avoid tibial fracture at the tip of a short rod.

Treatment of Type 1/CPT

The surgical approach to the pseudarthrosis depends on the preoperatively estimated amount of acute shortening of the tibia after debridement of the pseudarthrosis (Figs. 4 and 5). If the resulting bone defect is less than 3 cm, then a transversely placed skin incision is used that is centered on the pseudarthrosis. If the estimated acute shortening is more than 3 cm, the preferred approach utilizes a Z-shaped skin incision. After acute tibial shortening, the limbs of the Z-incision can be transposed to increase the width of the incision at the expense of the length. This incision also allows exposure of the tibia and fibula from the same skin incision and good skin closure at the end of operation (19). All retained hardware is extracted. Fibrous tissue at the site of CPT is excised to leave a healthy soft tissue bed. Debridement, rather than excision, of dead bone is performed till bleeding end is reached. An IM rod of suitable size is inserted. The choice of the type of the IM rod depends on the size of the tibia.

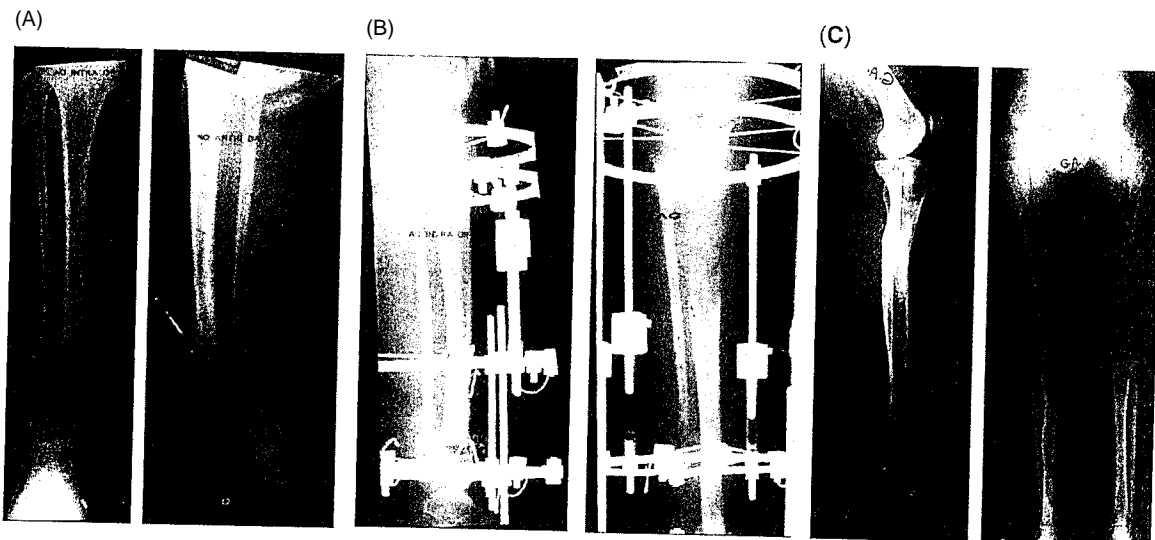


Figure 5 (A-C) Type II pseudarthrosis treatment. (A) Anteroposterior (AP) and lateral view radiographs of Type II pseudarthrosis in a 14-year-old girl after resection of bone ends. (B) Acute shortening and proximal osteotomy for lengthening of 10 cm. (C) AP and lateral views 11.5 years postoperatively show consolidation of CPT, good alignment, and equal leg lengths.

Immediate bone contact is obtained by acutely shortening the leg. This depends on the size of the bone defect after debridement and distal blood flow after acute leg shortening, which is monitored by Doppler ultrasound throughout the operation and postoperatively. If the bone defect is so great that it would kink the blood vessels and cause lack of blood flow to the foot, then partial acute shortening is done within the tolerance of the circulation, followed by gradual shortening in the following postoperative days at a rate of 2 to 3 mm/day until adequate bone contact is achieved.

Autogenous ICBG is harvested and packed around the bone ends. A three-ring Ilizarov external fixator is then applied with the limb aligned. Proximal metaphyseal osteotomy for limb lengthening is done percutaneously.

Postoperative compression of the pseudarthrosis is performed at a rate of one millimeter, twice weekly till complete bone contact and early bone healing is achieved. After consolidation of the pseudarthrosis is confirmed radiologically, the fixator is removed. The IM rod is left in place and eventually replaced by a longer one when the tibia outgrows the rod.

Treatment of Type 1/CPT

This type of CPT is amenable to closed distraction-compression without open surgery (Figs. 6 and 7). Preoperative analysis of the deformity is necessary so that a preconstructed Ilizarov external fixator is prepared the day before operation and sterilized. If the fibula is intact, then a percutaneous fibular osteotomy is done before fixator application; the pseudarthrosis itself is not disturbed. The preconstructed fixator is applied under image intensifier control for accurate hinge placement. The hinge is placed at the level of the apex of deformity on the convex side, with the hinge axis perpendicular to the plane of maximum deformity. Gradual deformity correction is started postoperatively at a rate calculated according to the method described by Herzenberg and Waanders (20). After complete deformity correction, the hinges and the distractor are replaced by straight rods and axial compression of the CPT is done until bone consolidation is achieved. The fixator is removed and a well-fitting above-knee cast is applied. As a secondary procedure, an IM rod is inserted percutaneously to protect against refractures.

After Treatment

The limb is fitted into knee-ankle-foot orthosis with a drop lock at the knee and solid ankle and gradually changed into patellar tendon-bearing orthosis near skeletal maturity when the tibia is well developed and thick enough to resist refracture. The patient is seen at three months, six months, and then yearly. Plain X rays are obtained to determine bone quality, evidence of refracture, gradually developing deformity, and length of the IM rod relative to the length of the tibia. Regular follow-up of the patient is necessary until skeletal maturity when the tibia attains normal size and good bone quality (12,13).

Results of Treatment

In our series of 17 cases of CPT, 36 operations were performed (17 procedures for the original pseudarthrosis and 19 for refractures). It was possible to obtain union of the pseudarthrosis with

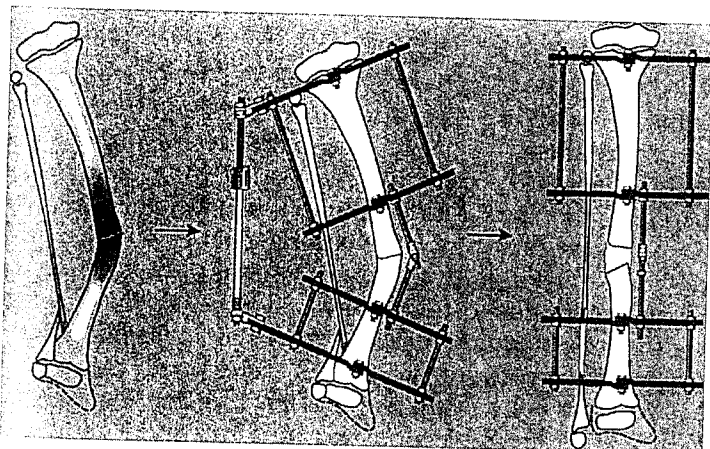


Figure 6 Type III treatment. Application of a preconstructed Ilizarov external fixator (the hinge is placed at the level of the deformity apex on the convex side with its axis perpendicular to the plane of maximum deformity). Gradual distraction of the pseudarthrosis for deformity correction is followed by axial compression until bone consolidation is achieved.




Figure 7 (A-C) Type III pseudarthrosis treatment. (A) Anteroposterior and lateral view radiographs of Type III pseudarthrosis with intramedullary rod previously applied and stress fracture. (B) Postoperative radiographs after application of Ilizarov external fixator for distraction of the pseudarthrosis and deformity correction. (C) Follow-up radiographs show consolidation of the pseudarthrosis and good alignment.

every treatment. The refracture rate was 68% when only the Ilizarov device was used; however, this rate was reduced to 29% when the IM rod was combined with the Ilizarov device. Patients, who were followed until skeletal maturity, have had their tibiae healed with normal cross sectional area and have experienced no refracture afterwards (Fig.5). The best results were obtained in Type III and Type I cases; less-favorable results were obtained in patients with Type II, who had experienced several previously failed operations.

COMPLICATIONS

The most dreaded complication in the treatment of CPT is refracture of the tibia after it is healed. Refracture can occur at the site of previous pseudarthrosis, regenerate bone, or pin site hole. Predisposing factors to refracture are residual deformity, tenuous healing of pseudarthrosis with hourglass tibial constriction, pin site hole in the bone, stress riser at the tip of a short IM rod, and premature removal of external fixator before consolidation of regenerate bone (1,6,14,15). Treatment of refracture follows the same protocol as treatment of the original pseudarthrosis.

Other complications, such as peroneal nerve palsy during lengthening and deformity correction, may necessitate nerve decompression at the level of head of the fibula. Valgus deformity of the ankle is corrected by supramalleolar osteotomy and acute deformity correction, Equinus contracture of the ankle is corrected by combined soft tissue release and distraction of the joint; supramalleolar osteotomy is used to correct equinus deformity if the ankle is ankylosed and not amenable to arthrodiastasis. Leg-length discrepancy is corrected by leg lengthening if the discrepancy was of clinical significance; a proximal metaphyseal osteotomy is utilized to equalize leg length during treatment of the CPT or afterwards (13).

FUTURE DIRECTIONS

The introduction of distraction histogenesis, based on the principle of tension stress effect, has revolutionized the treatment of several challenging orthopedic problems including CPT. However, the shortcoming of this technique is that the natural history of CPT is not modified and the affected tibia will remain dysplastic and prone to fractures until skeletal maturity. Realizing that the primary problem in the treatment of CPT is a biological one, where the osteogenic power at the pseudarthrosis site is lacking, future investigations should focus on finding out treatment modalities that locally stimulate osteogenesis and bone repair. Of great promise is the application of local gene therapy in which mesenchymal stem cells are genetically modified to both produce and respond to osteoinductive growth factors with the goal of developing a tissue engineering strategy for new bone formation and fracture healing. Should a successful clinical program of local gene therapy be established, this treatment modality

would modify the natural history of CPT, reduce the tendency to refracture, and may obviate the need for open bone grafting procedure (21).

REFERENCES

1. Boyd HB. Pathology and natural history of congenital pseudarthrosis of the tibia. *Clin Orthop* 1982; 166:5-13.
2. Crawford AH, Schorry EK. Neurofibromatosis in children: the role of the orthopaedist. *J Am Acad Orthop Surg* 1999; 7(4):217-230.
3. Wientroub S, Grill F. Congenital pseudarthrosis of the tibia: Part I. European Pediatric Orthopedic Society multicenter study of congenital pseudarthrosis. *J Pediatr Orthop B* 2000; 9(1):1-2.
4. Andersen KS. Radiological classification of congenital pseudarthrosis of the tibia. *Acta Orthop Scand* 1973; 44(6):719-727.
5. Morrissy RT. Congenital pseudarthrosis of the tibia: factors that affect results. *Clin Orthop* 1982; 166:21-27.
6. Kristiansen LP, Steen H, Terjesen T. Residual challenges after healing of congenital pseudarthrosis of the tibia. *Clin Orthop* 2003; 414:228-237.
7. Joseph B, Somaraju VV, Shetty SK. Management of congenital pseudarthrosis of the tibia in children under 3 years of age: effect of early surgery on union of the pseudarthrosis and growth of the limb. *J Pediatr Orthop* 2003; 23(6):740-746.
8. Codavilla A. On the cure of congenital pseudarthrosis of the tibia by means of periosteal transplantation. *J Bone Joint Surg* 1906; VII:163-170.
9. Umber JS, Moss SW, Coleman SS. Surgical treatment of congenital pseudarthrosis of the tibia. *Clin Orthop* 1982; 166:28-33.
10. Weiland AI, Weiss AP, Moore JR, Tolo VT. Vascularized fibular grafts in the treatment of congenital pseudarthrosis of the tibia. *J Bone Joint Surg Am* 1990; 72:654-662.
11. Boero S, Catagni M, Donzelli O, Facchini R, Frediani PY. Congenital pseudarthrosis of the tibia associated with neurofibromatosis-I: treatment with Ilizarov's device. *J Pediatr Orthop* 1997; 17(5):675-684.
12. Dobbs MB, Rich MM, Gordon JE, Szymanski DA, Schoenecker PL. Use of an intramedullary rod for the treatment of congenital pseudarthrosis of the tibia. A long-term follow-up study. *J Bone Joint Surg Am* 2004; 86(6):1186-1197.
13. El-Rosasy MA, Paley D, Herzenberg JE. Ilizarov treatment for congenital pseudarthrosis of the tibia. Annual Meeting of the American Academy of Orthopaedic Surgeons, Orlando, FL, Mar 16, 2000.
14. Johnston CE H. Congenital pseudarthrosis of the tibia: results of technical variations in the Charnley-Williams procedure. *J Bone Joint Surg Am* 2002; 84(10):1799-1810.
15. Paley D, Catagni M, Argnani F, Prevot I, Bell D, Armstrong P. Treatment of congenital pseudarthrosis of the tibia using the Ilizarov technique. *Clin Orthop* 1992; 280:81-93.
16. Hermanns-Sachwen B, Senderek J, Alfer I, et al. Vascular changes in the periosteum of congenital pseudarthrosis of the tibia. *Pathol Res Pract* 2005; 201(4):305-312.
17. Paley D, Herzenberg JE, Tetsworth K, McKie I, Bhave A. Deformity planning for frontal and sagittal plane corrective osteotomies. *Orthop Clin North Am* 1994; 25(3):425-465.
18. Sofield HA. Congenital pseudarthrosis of the tibia. *Clin Orthop* 1971; 76:33-42.
19. Simpson AH, Andrews C, Giele H. Skin closure after acute shortening. *J Bone Joint Surg Br* 2001; 83(5):668-671.
20. Herzenberg JE, Waanders NA. Calculating the rate and duration of distraction for deformity correction with the Ilizarov technique. *Orthop Clin North Am* 1991; 22(4):601-611.
21. Baltzer AW, Lieberman JR. Regional gene therapy to enhance bone repair. *Gene Ther* 2004; 11(4):344-350.